
**PATIENT**

Dolce Bickle

**PRESENTING CLINICAL SIGNS**

History: Heart murmur. Chronic occasional vomiting. Elevated kidney values, UTI, repeat culture neg after 14 d of clav but still elevated.

**SPECIES**

Feline

**ECHOCARDIOGRAM FINDINGS**

2D, m-mode, color flow and doppler imaging is available. The left ventricular wall is normal in dimension. There is a diffusely hyperechoic endocardium consistent with age-related fibrosis. Minimal remodeling. The papillary muscles are hyperechoic. The left atrium is normal in size. The right atrium is normal in size. The right ventricle appears normal. The mitral valve is normal in structure and mobility. No MR. The tricuspid valve appears normal in structure and mobility. No TR. Blood flow through both the LVOT and RVOT are normal in velocity. No effusions. No obvious cardiac tumors.

**BREED**

DSH

**SEX**

Female Spayed

**CARDIAC CHART**
**AGE**

16 years

FELINE CARDIAC PARAMETERS	BODY WEIGHT (kg)	HR (BPM)	IVSd (cm) <small>(Moise, Pipers)</small>	LVIDd (cm) <small>(Moise, Pipers)</small>	LVWd (cm) <small>(Moise, Pipers)</small>	FS (%)	EF (%)
<b>NORMAL PARAMETER</b>	-----	150-240	0.35-0.55	<2 (mean 1.5)	3.5-0.55	35-67	80-100
<b>PATIENT</b>	2.9	190	0.45	1.04	0.41	62	93
FELINE CARDIAC PARAMETERS	LA/AO <small>(Boon)</small>	LA/AO HEART BASE (Swe) <small>(Abbott)</small>	LA 2D short axis Base view (cm) <small>(Abbott)</small>	LVOT VEL  (m/s)	RVOT VEL  (m/s)	E max  (m/s)	
<b>NORMAL</b>	<1.5	<1.3	<1.2	<1.6	<1.3	<0.9	
<b>PATIENT</b>	1.3	1.2	1.0	1.1	1.4	NM	
*Note: All measurements based upon multi-modal images and methods. An average value is reported. Adapted from June Boon, Veterinary Echocardiography, 1998 Abbott J & MacLean H JVIM 2006;20: 111-119, Moise et al. Am J Vet Res 47:1476, 1986. Pipers et al. Am J Vet Res 40:882, 1979.							

**INTERPRETED BY**

 Maggie Machen Lamy,  
 DVM DACVIM  
 (Cardiology)

**IMAGING PERFORMED BY**

Kelly Reschny, RVT

**HOSPITAL NAME**

 East Credit Veterinary  
 Hospital

**REFERRING VET**

Dr. Webster

**INTERPRETATION OF THE FINDINGS & FURTHER RECOMMENDATIONS**

Overtly normal geriatric cardiac structure and function. Mild fibrosis of the left ventricular wall is noted, which is likely a normal age-related variant. No significant valve leaks are noted, and flow through the great vessels is normal in velocity. No definitive cause is identified for the murmur in this study, making it likely physiologic in origin (i.e. secondary to tachycardia, volume changes, etc.). Given these findings and a normal LA dimension, no medications are indicated.

**INVOICE**

28246

Monitor at home for signs of cardiac compromise, including respiratory changes and/or signs of a blood clot event (paralysis, neurologic changes).

**DATE**

1/11/23

Recommend recheck echocardiogram in 1 year to assess for any progressive issues or development of disease the pre-existing murmur may mask.



**PATIENT**

Dolce Bickle

**SPECIES**

Feline

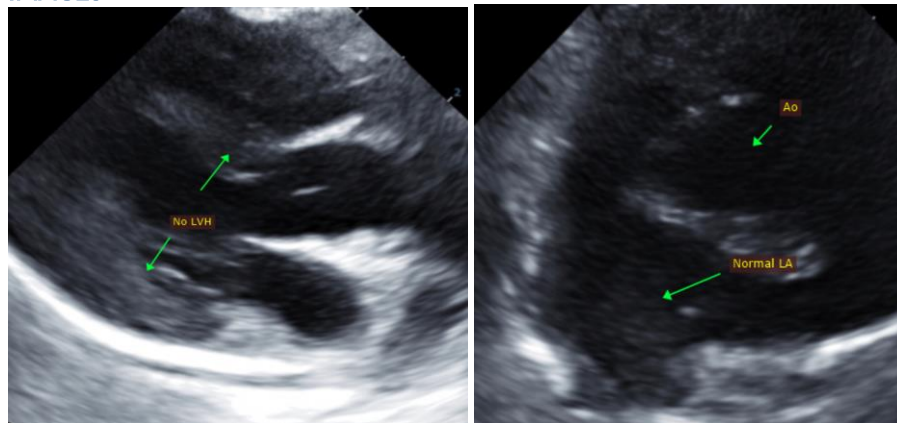
**BREED**

DSH

**SEX**

Female Spayed

**IMAGES**



**AGE**

16 years

The information and recommendations provided are based on the images presented by the referring veterinarian. No evaluation can be communicated regarding pathology that was not visible in the image/video clips provided.

**WEIGHT**

6.3lbs

Thank you for this referral. This report was generated using transcription software, and minor dictation errors may be present. If the clinical or image interpretation does not parallel your findings or if I can be of any further assistance, please contact me.

**INTERPRETED BY**

Maggie Machen Lamy,  
DVM DACVIM  
(Cardiology)

**Maggie Machen Lamy, DVM**  
Diplomate of the American College of Veterinary Internal Medicine (Cardiology)  
info@sonopath.com

**IMAGING  
PERFORMED BY**

Kelly Reschny, RVT

**HOSPITAL NAME**

East Credit Veterinary  
Hospital

**REFERRING VET**

Dr. Webster

**INVOICE**

28246

**DATE**

1/11/23